Previously Abandoned Leads without Infection: Should These Be Removed or Not?

의정부 성모병원
김주연

ICD upgrade

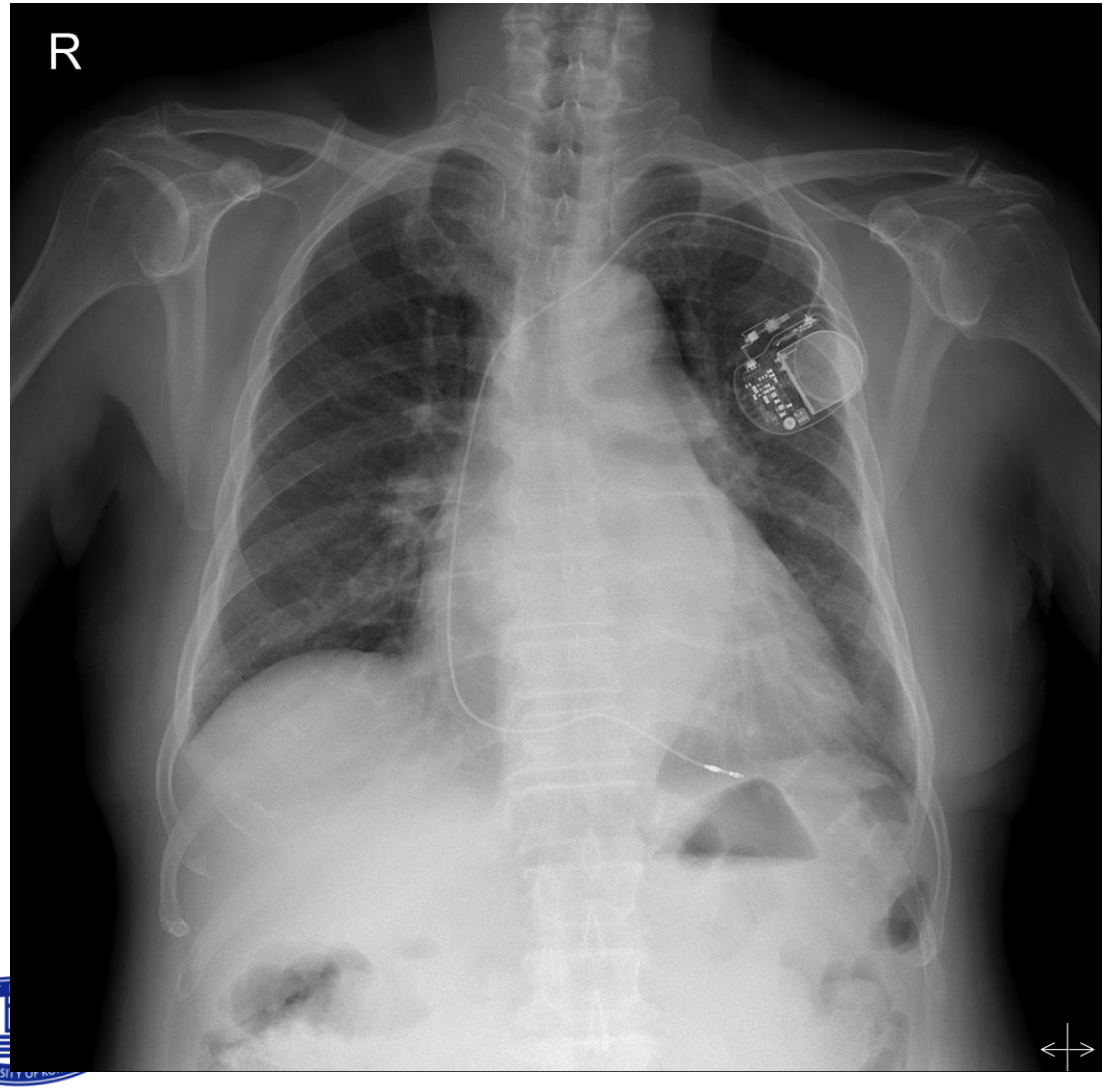

LV lead failure

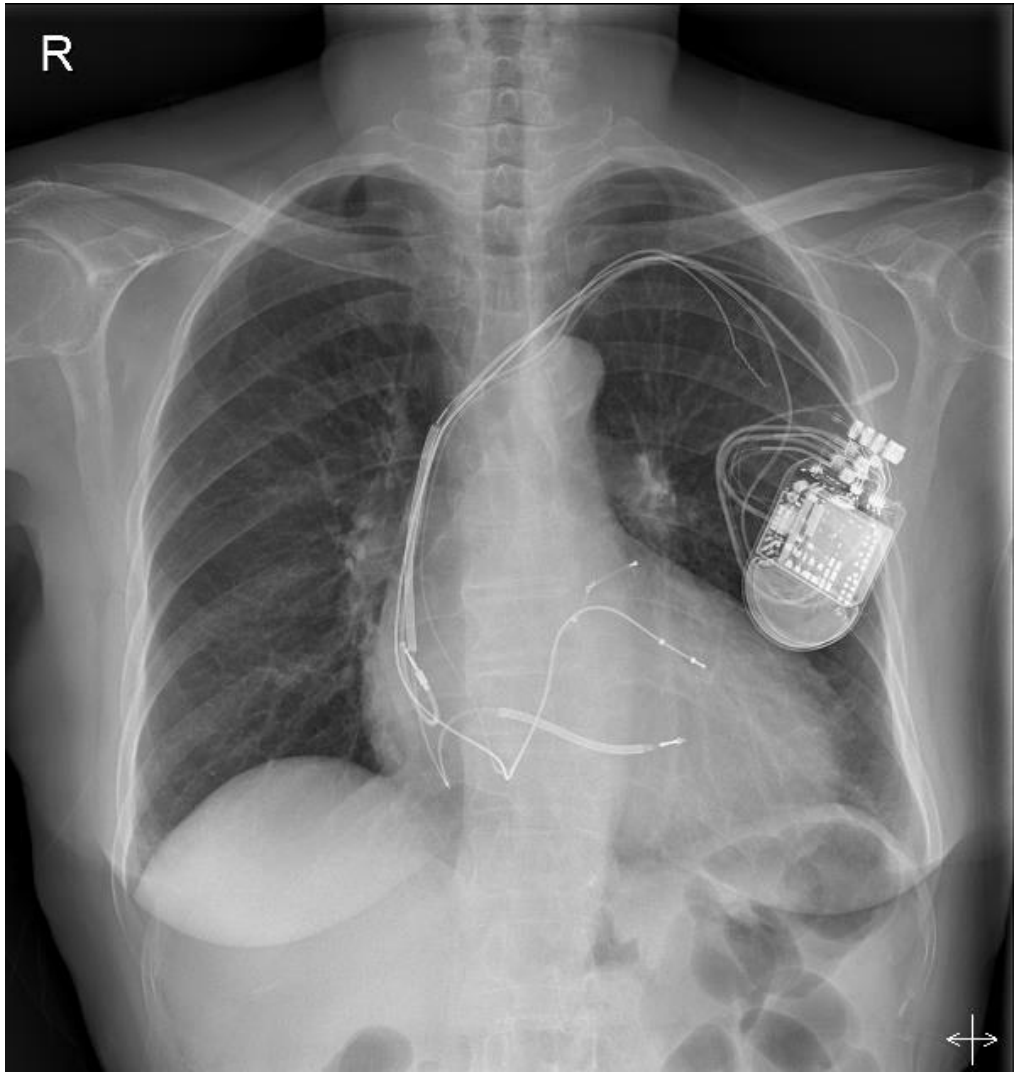

2008, Passive lead

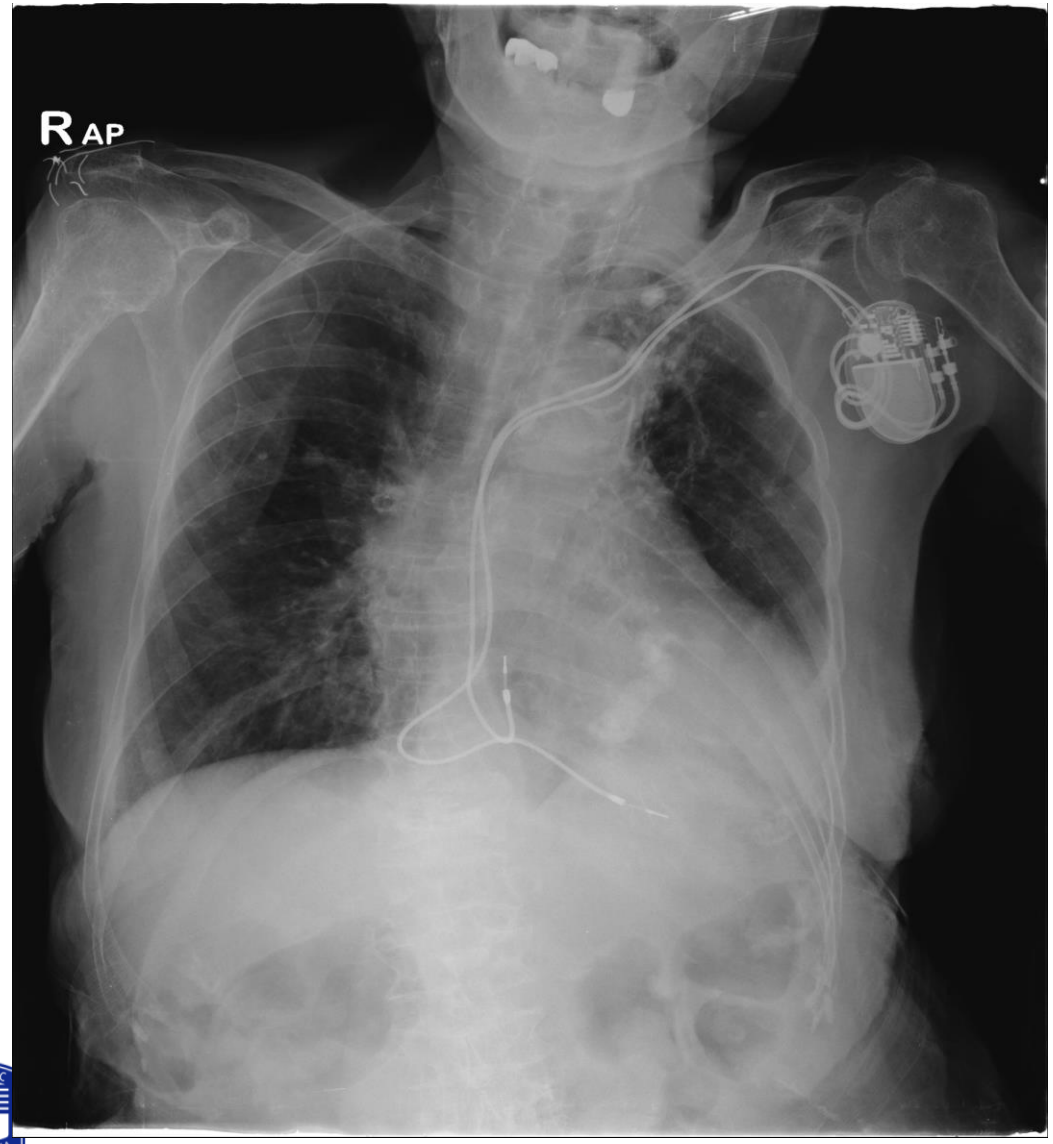

2014, Active lead

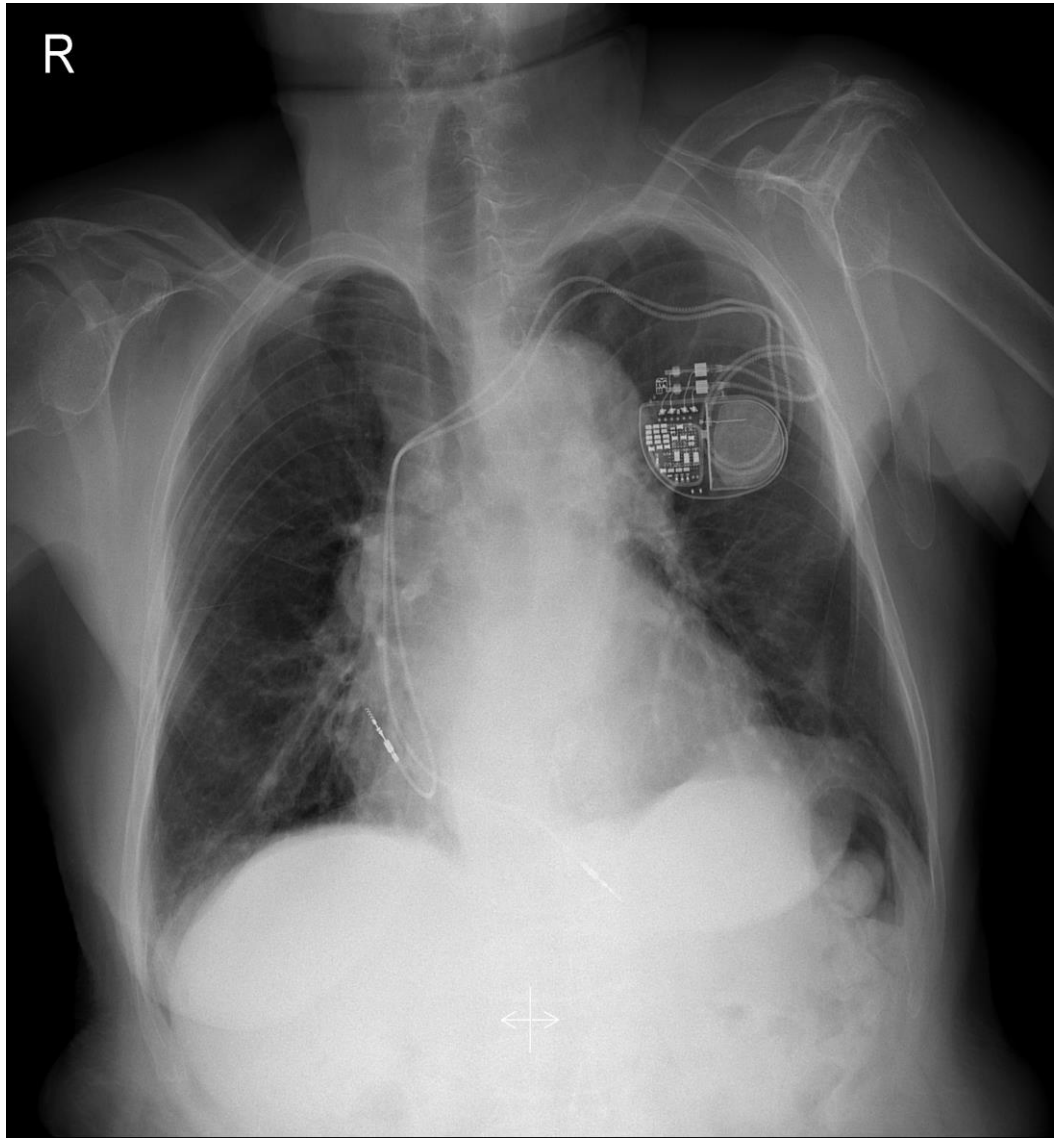

Expert Consensus for lead extraction

- Recommendations for lead extraction apply only to those patients in whom the benefits of lead removal outweigh the risks when assessed based on individualized patient factors and operator specific experience and outcomes.

Heart Rhythm, Vol 6, No 7, July 2009

When should we consider remove the abandoned lead?

- Complication (+)
- Complication high risk
- Complication (-), 다른 치료나 진단에 방해 될 때

Incidence of complications

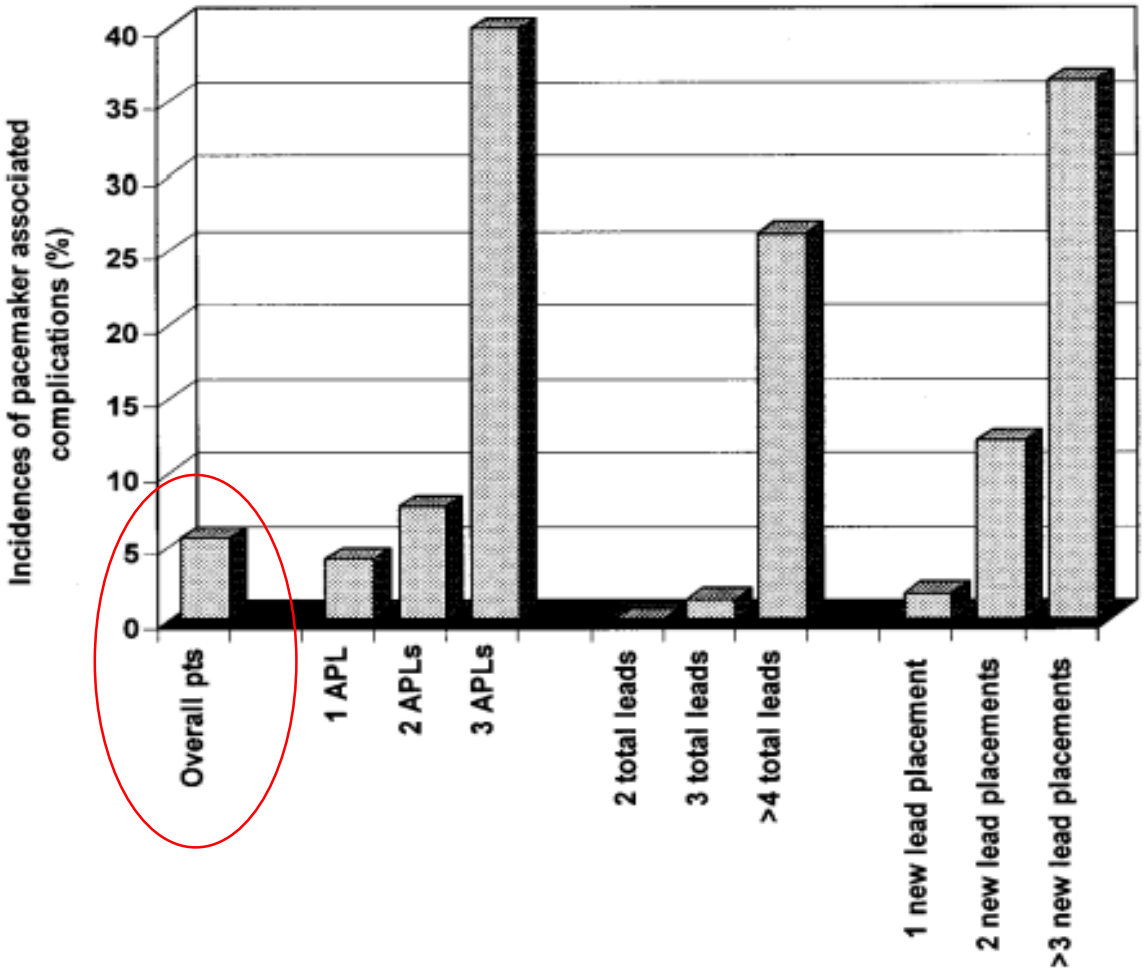

Journal of Interventional Cardiac Electrophysiology 4, 493–499(2000)

Complications from abandoned pacemaker leads

- In general, non-functional transvenous leads can be abandoned with low risk.

- Infection
- Venous occlusion
- Interference with functioning leads (oversensing caused by spurious signals arising d/t contact of functioning lead)
- Migration of leads
- Arrhythmias

Venous occlusion

Facial edema

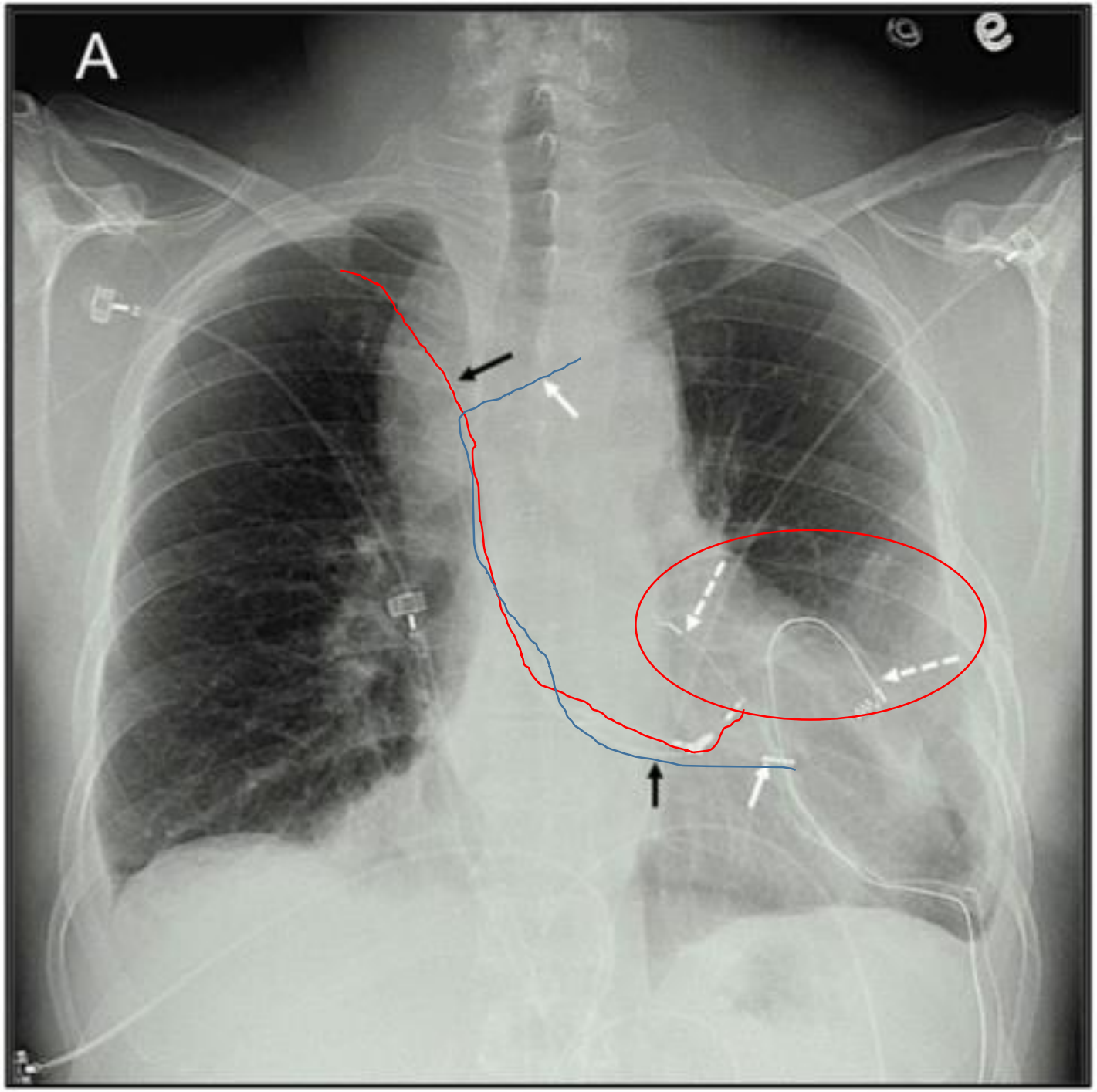

J Card Surg 2014;29:406–409

SVC total occlusion

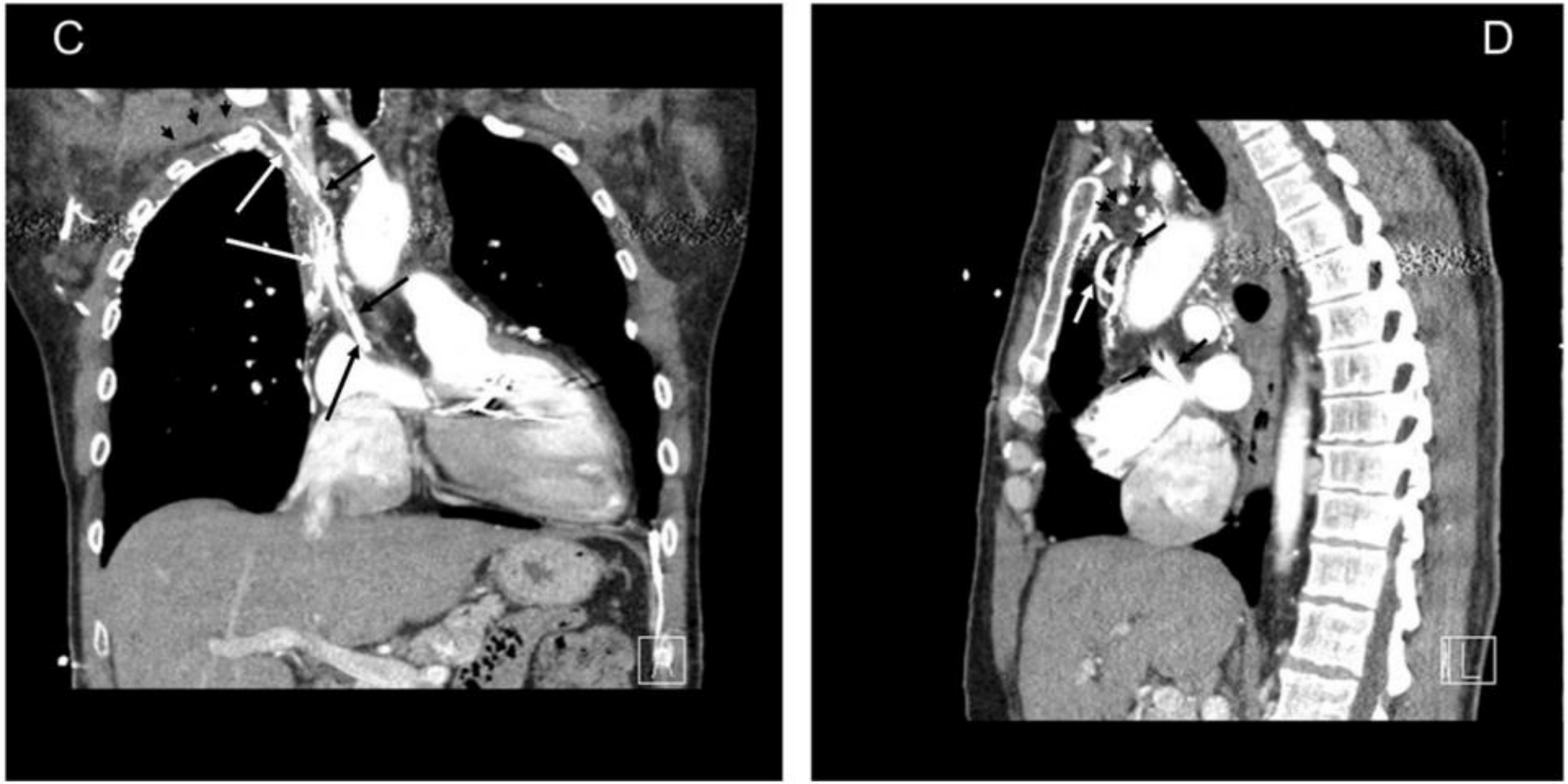

J Card Surg 2014;29:406–409

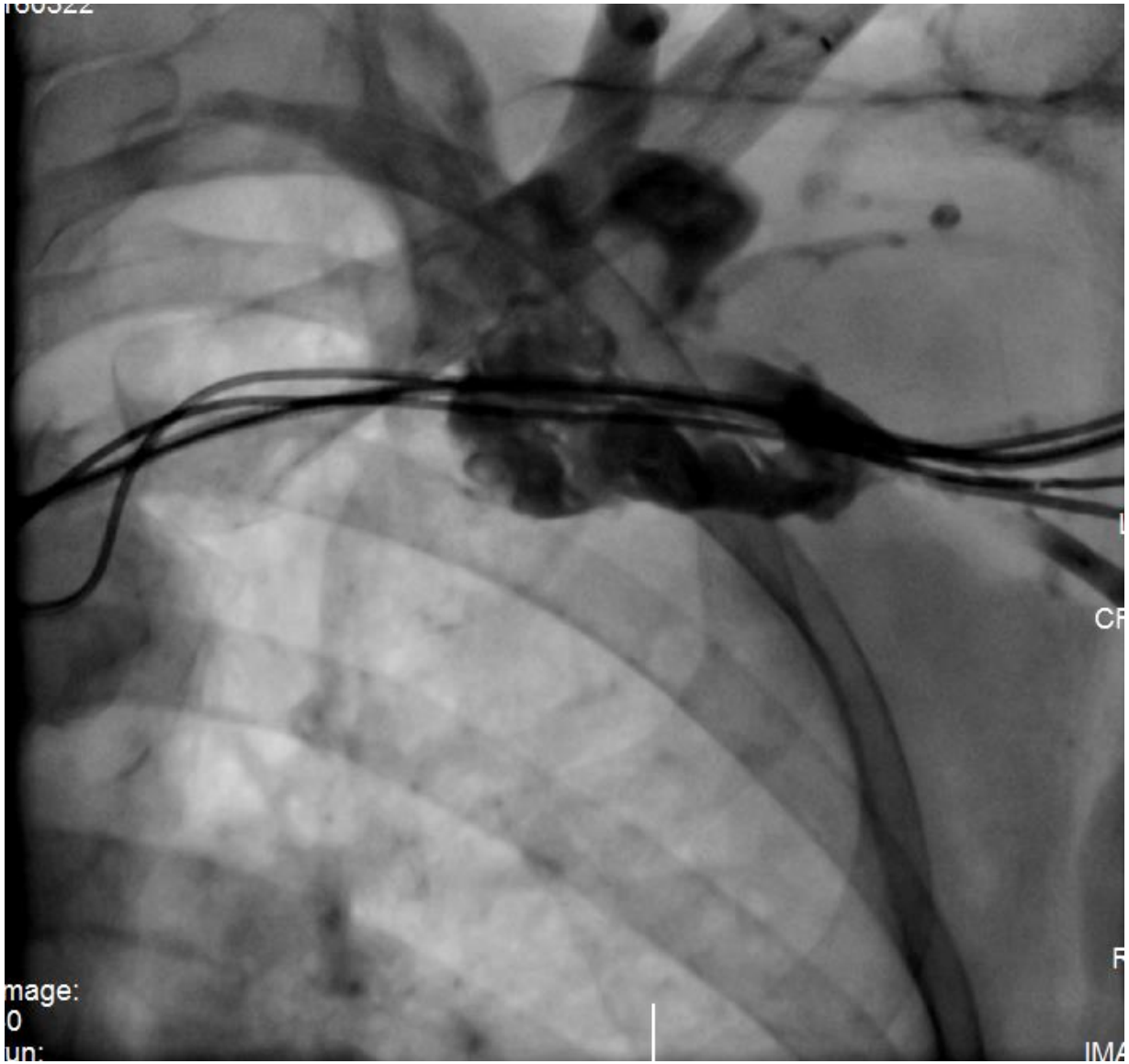
mage:
0
un:

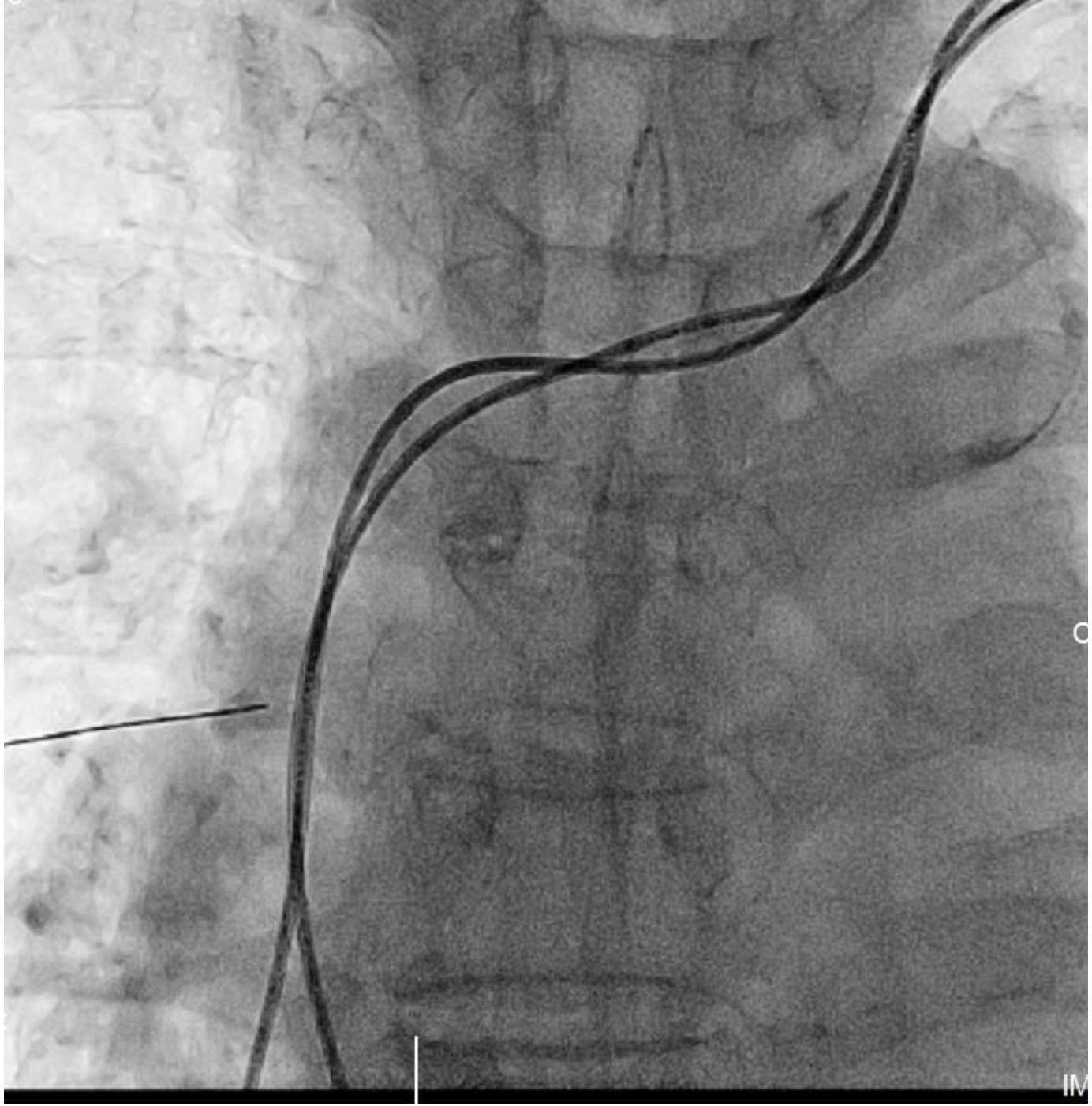
C
IM

Indications for transvenous lead extraction (Thrombosis or Venous stenosis)

Thrombosis or Venous Stenosis

Class I

1. Lead removal is recommended in patients with clinically significant thromboembolic events associated with thrombus on a lead or a lead fragment. *(Level of evidence: C)*
2. Lead removal is recommended in patients with bilateral subclavian vein or SVC occlusion precluding implantation of a needed transvenous lead. *(Level of evidence: C)*
3. Lead removal is recommended in patients with planned stent deployment in a vein already containing a transvenous lead, to avoid entrapment of the lead. *(Level of evidence: C)*
4. Lead removal is recommended in patients with superior vena cava stenosis or occlusion with limiting symptoms. *(Level of evidence: C)*
5. Lead removal is recommended in patients with ipsilateral venous occlusion preventing access to the venous circulation for required placement of an additional lead when there is a contraindication for using the contralateral side (e.g. contralateral AV fistula, shunt or vascular access port, mastectomy). *(Level of evidence: C)*

Class IIa

1. Lead removal is reasonable in patients with ipsilateral venous occlusion preventing access to the venous circulation for required placement of an additional lead, when there is no contraindication for using the contralateral side. *(Level of evidence C)*

Heart Rhythm 2009;6

Thrombosis or Venous stenosis

- Venous thrombosis alone is not an indication for lead extraction.

- Symptoms (+)
- Occlusion prevents the application of pacemaker

Arrhythmia

Focal/Normal voltage

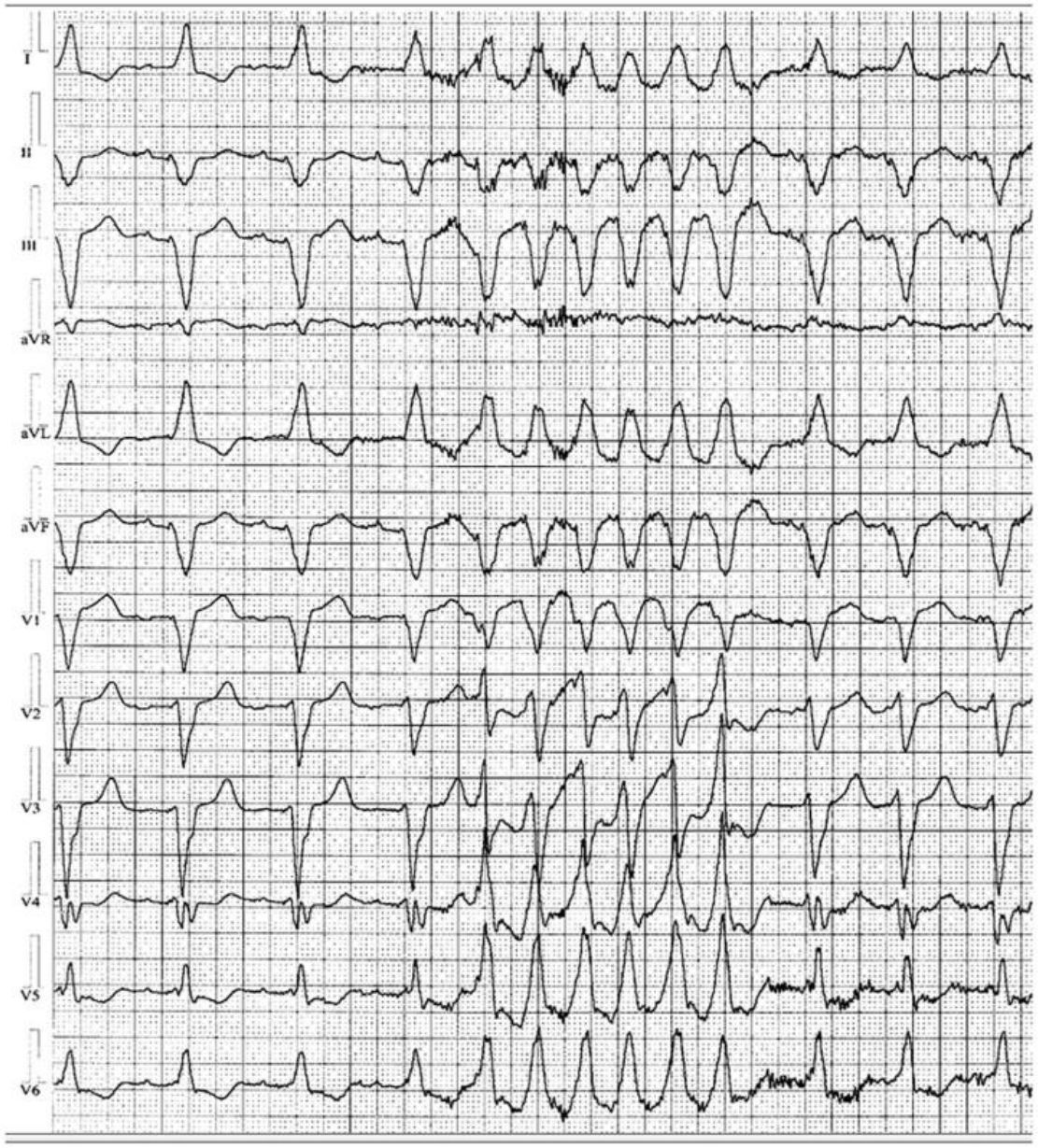

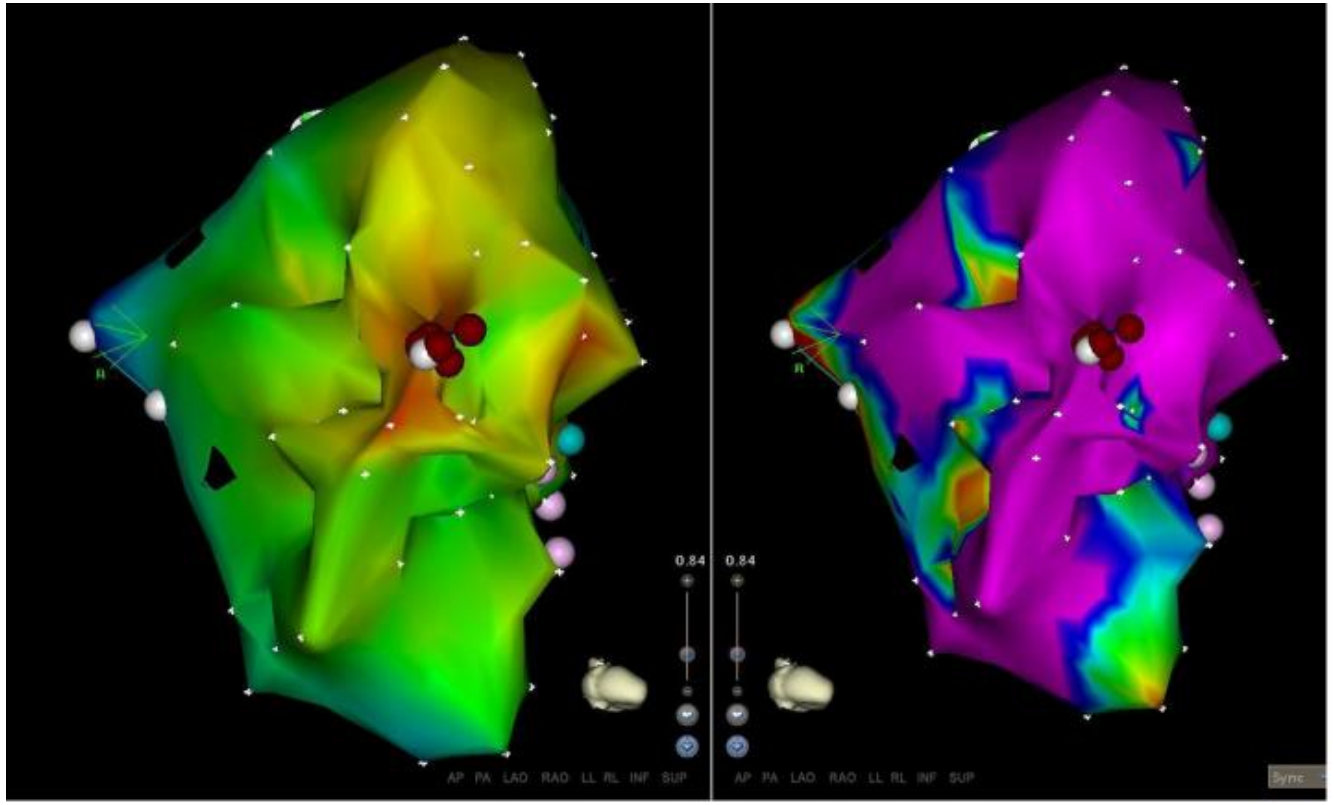

Heart Rhythm Case Reports 2015;1:126 – 129

VT secondary to abandoned epicardial pacemaker lead

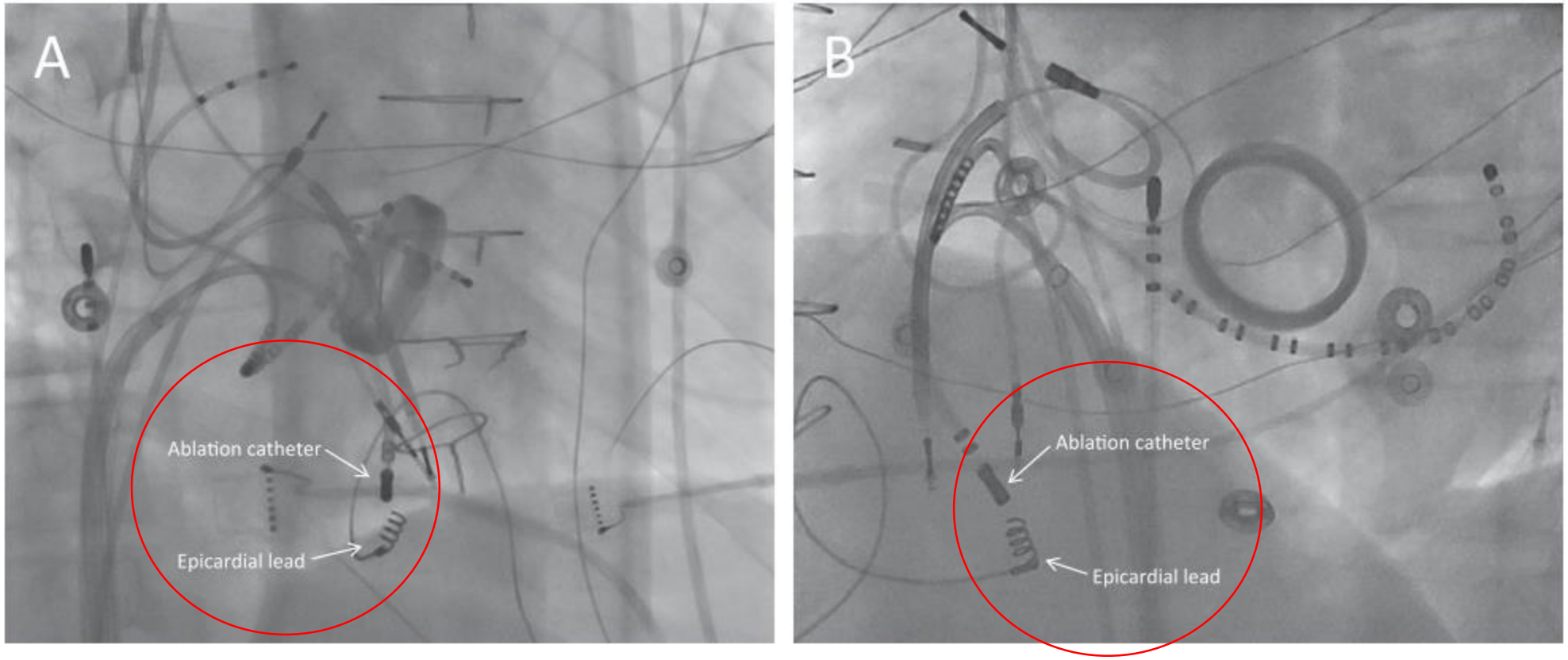

Heart Rhythm Case Reports 2015;1:126 – 129

Migration of leads

Migration of lead

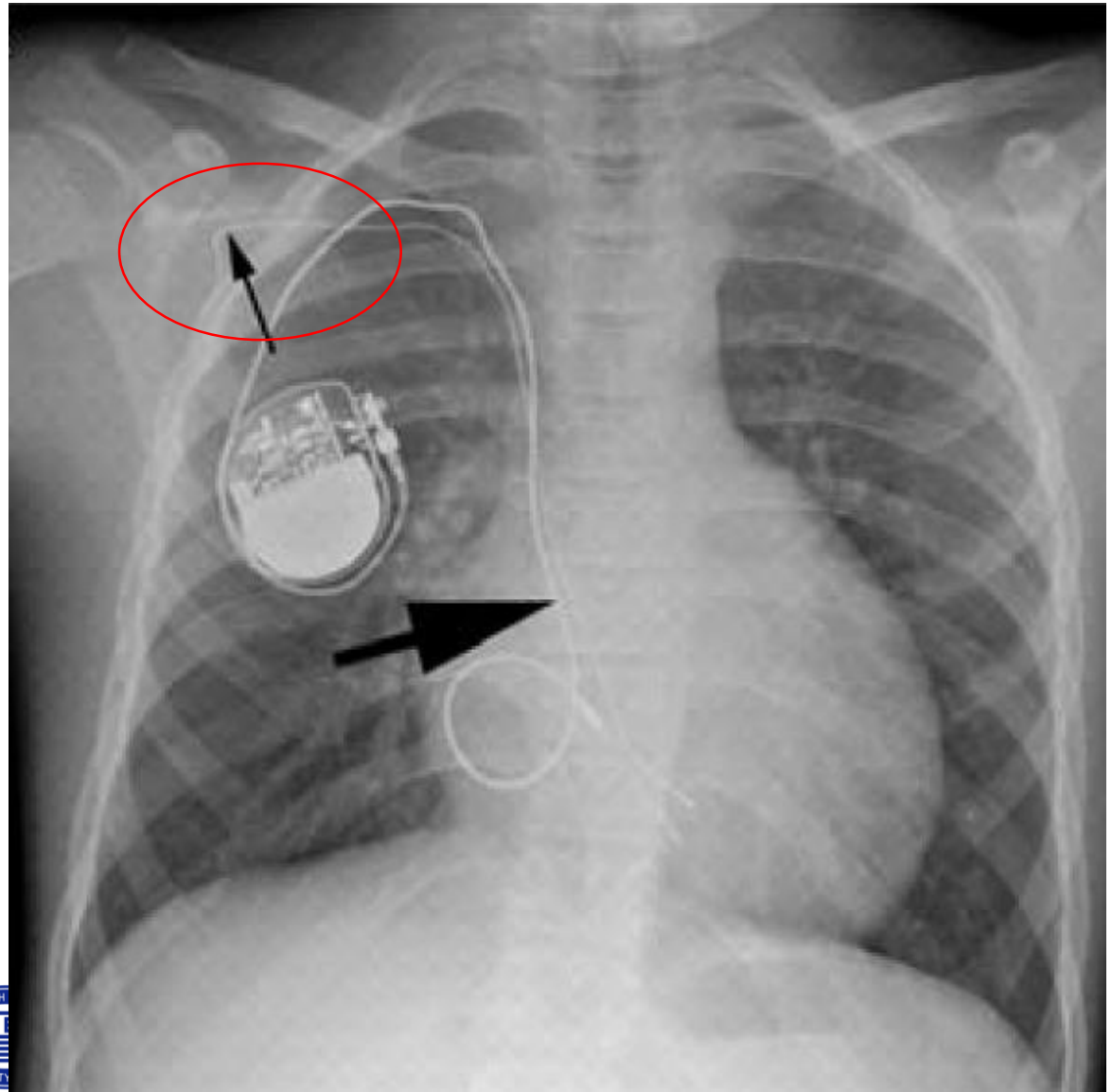

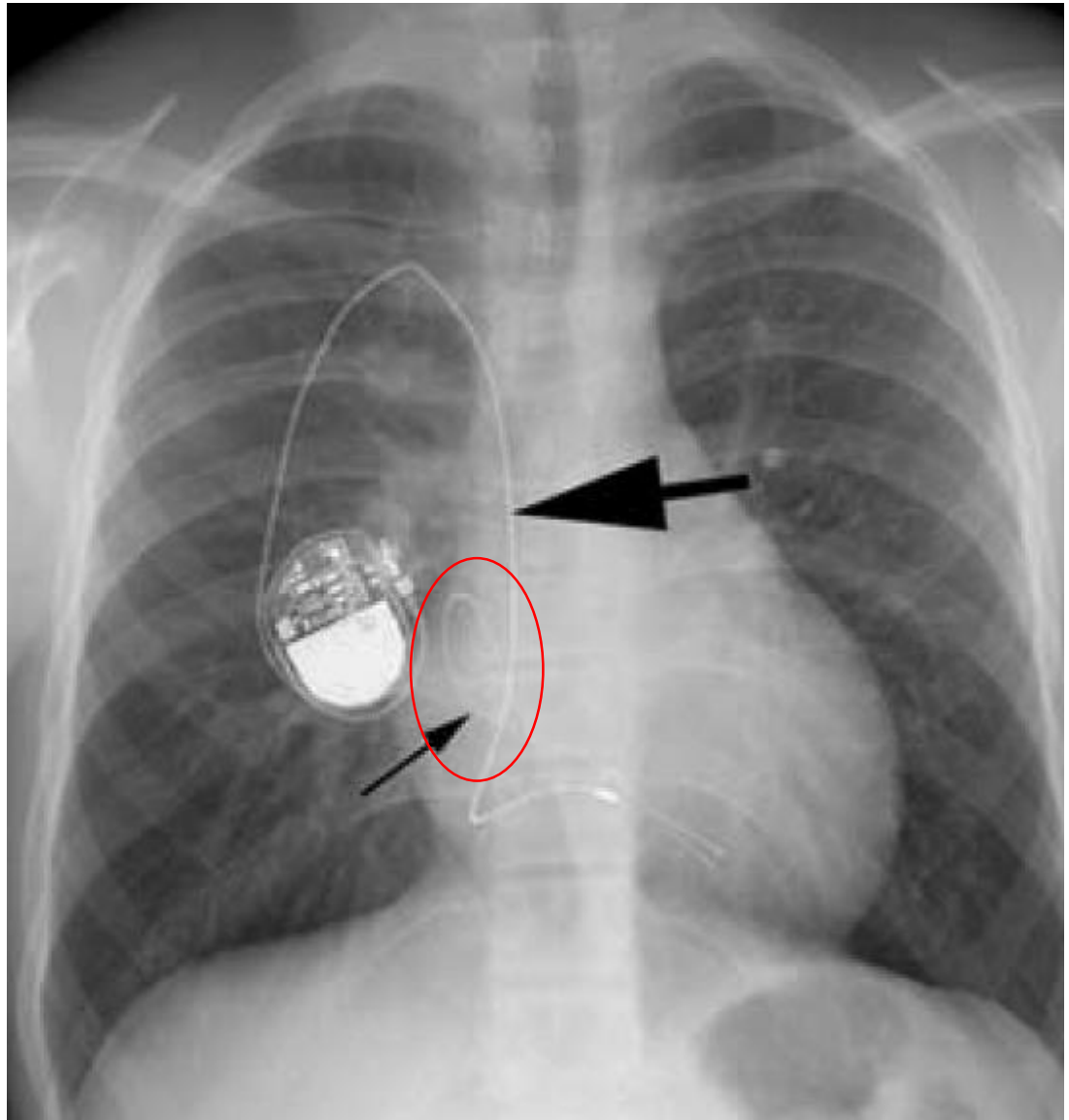

Class I indication for lead extraction

Functional Leads Non Functional Leads

Class I

1. Lead removal is recommended in patients with life threatening arrhythmias secondary to retained leads. *(Level of evidence: B)*
2. Lead removal is recommended in patients with leads that, due to their design or their failure, may pose an immediate threat to the patients if left in place. (e.g. Telectronics ACCUFIX J wire fracture with protrusion). *(Level of evidence: B)*
3. Lead removal is recommended in patients with leads that interfere with the operation of implanted cardiac devices. *(Level of evidence: B)*
4. Lead removal is recommended in patients with leads that interfere with the treatment of a malignancy (radiation/reconstructive surgery). *(Level of evidence: C)*

Heart Rhythm 2009;6

Class II indication for lead extraction

Class IIa

1. Lead removal is reasonable in patients with leads that due to their design or their failure pose a threat to the patient, that is not immediate or imminent if left in place. (e.g. Telectronics ACCUFIX without protrusion) *(Level of evidence C)*
2. Lead removal is reasonable in patients if a CIED implantation would require more than 4 leads on one side or more than 5 leads through the SVC. *(Level of evidence C)*
3. Lead removal is reasonable in patients that require specific imaging techniques (e.g. MRI) and can not be imaged due to the presence of the CIED system for which there is no other available imaging alternative for the diagnosis. *(Level of evidence: C)*

Class IIb

1. Lead removal may be considered at the time of an indicated CIED procedure, in patients with non-functional leads, if contraindications are absent. *(Level of evidence C)*
2. Lead removal may be considered in order to permit the implantation of an MRI conditional CIED system. *(Level of evidence: C)*

Class III indication for lead extraction

Class III

1. Lead removal is not indicated in patients with non-functional leads if patients have a life expectancy of less than one year. *(Level of evidence C)*
2. Lead removal is not indicated in patients with known anomalous placement of leads through structures other than normal venous and cardiac structures, (e.g. subclavian artery, aorta, pleura, atrial or ventricular wall or mediastinum) or through a systemic venous atrium or systemic ventricle. Additional techniques including surgical backup may be used if the clinical scenario is compelling. *(Level of evidence: C)*

Heart Rhythm 2009;6

MRI

Potential adverse effect of MRI

- Radiofrequency-induced heating of the lead tips
- Pacing inhibition/dysfunction
- Asynchronous pacing with the possibility of induction of atrial or ventricular tachyarrhythmias
- Change or loss of programmed data
- Changes in capture threshold

Magnetic resonance in patients with implanted cardiac devices

Recommendations	Class [a]	Level [b]	Ref. [c]
1) Conventional cardiac devices. In patients with conventional cardiac devices, MR at 1.5 T can be performed with a low risk of complications if appropriate precautions are taken (see additional advice).	IIb	B	160–172
2) MR-conditional PM systems. In patients with MR-conditional PM systems, MR at 1.5 T can be done safely following manufacturer instructions.	IIa	B	173

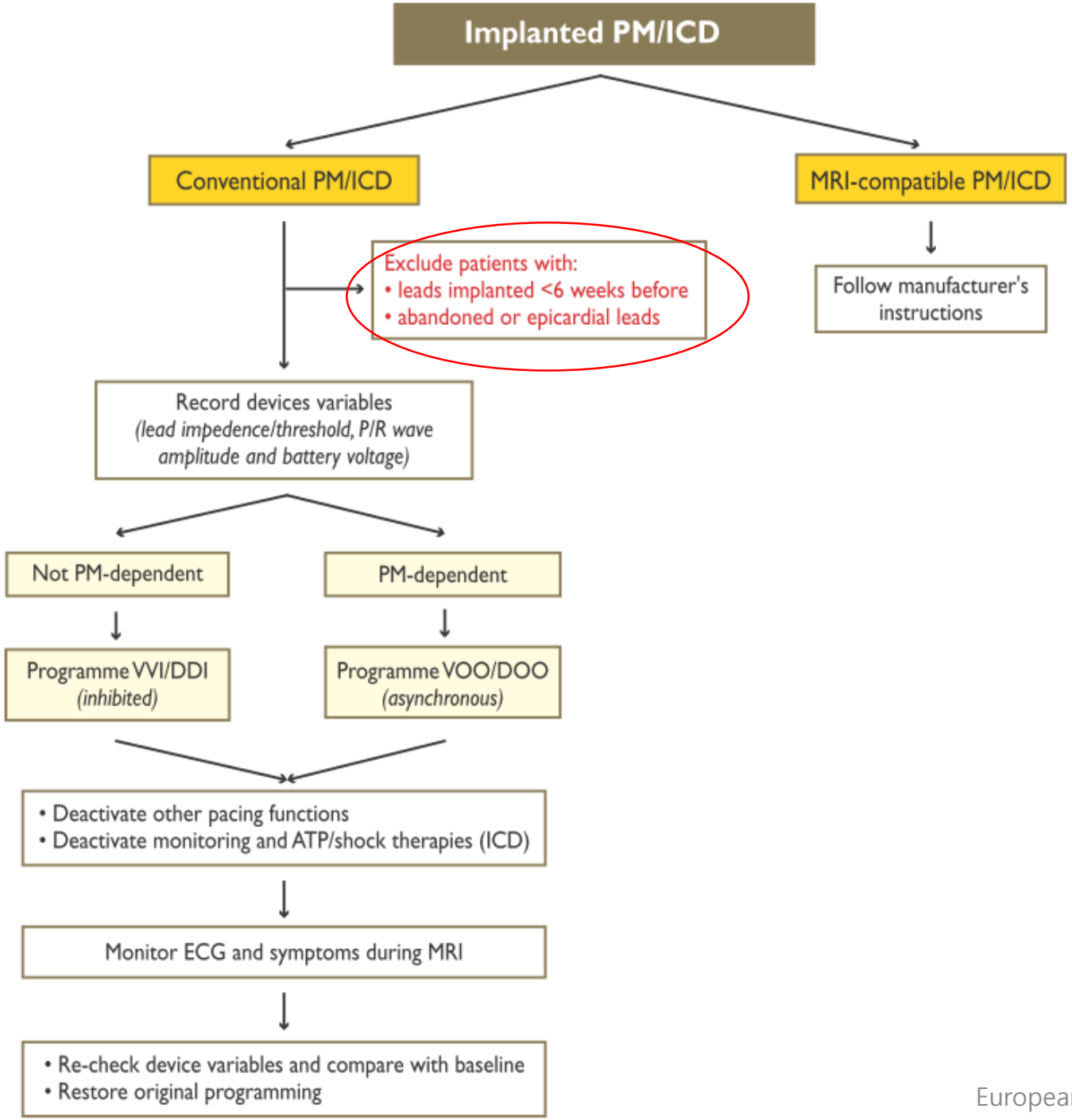

European Heart Journal (2013) 34, 2281–2329

Safety and Outcomes of Magnetic Resonance Imaging in Patients with Abandoned Pacemaker and Defibrillator Leads

JOHN V. HIGGINS, M.D.,* JOSEPH J. GARD, M.D.,† SETH H., SHELDON, M.D.,‡
RAUL E. ESPINOSA, M.D.,‡ CHRISTOPHER P. WOOD, M.D.,§ JOEL P. FELMLEE, PH.D.,§
YONG-MEI CHA, M.D.,‡ SAMUEL J. ASIRVATHAM, M.D.,‡ CONNIE DALZELL, R.N.,‡
NANCY ACKER, R.N.,‡ ROBERT E. WATSON, JR., M.D, PH.D.,§
and PAUL A. FRIEDMAN, M.D.‡

From the *Department of Internal Medicine, Mayo Clinic, Rochester, Minnesota; †Department of Cardiology, Oklahoma Heart Institute, Tulsa, Oklahoma; ‡Department of Cardiovascular Diseases, Mayo Clinic, Rochester, Minnesota; and §Department of Radiology, Mayo Clinic, Rochester, Minnesota

Introduction: *Abandoned cardiovascular implantable electronic device (CIED) leads remain a contraindication to magnetic resonance imaging (MRI) studies, largely due to in vitro data showing endocardial heating secondary to the radiofrequency field. We tested the hypothesis that abandoned CIED leads do not pose an increased risk of clinical harm for patients undergoing MRI.*

Methods: *This single-center retrospective study examined the outcomes of patients who had device generators removed before MRI, rendering the device leads abandoned. Information was gathered through chart review. Data collected included lead model, pacing threshold before MRI, anatomic region examined, threshold data after generator reimplantation, and clinical patient outcome.*

Results: *Patients (n = 19, 11 men and eight women) ranged in age from 19 to 85 at the time of MRI. There was a mean of 1.63 abandoned leads at the time of imaging; none of the leads were MRI conditional. Of the three implantable cardioverter defibrillator (ICD) leads, two of three were dual coil. Most (31/35) of the scans performed were of the central nervous system, including head and spinal imaging. There were no adverse events associated with MRI in any of these patients with abandoned leads within 7 days of the scan. No lead malfunctions or clinically significant change in pacing thresholds were noted with generator reimplantation.*

Conclusion: *The use of MRI in patients with abandoned cardiac device leads appears feasible when performed under careful monitoring, with no adverse events, although the experience is small. MRI did not affect the function of leads that were subsequently reconnected to a cardiac device. (PACE 2014; 37:1284–1290)*

Summary

- Consider remove when it can be extracted easily.

- Complication 이 생긴 경우
- Complication 이 발생할 가능성이 높은 경우
- Complication 은 없지만 다른 치료나 진단에 방해가 되는 경우 (MRI, radiation/reconstruction surgery)
- Multiple leads